COMPLETE DENTURE OCCLUSSION

Occlusion:

Any contact between teeth of opposing dental arch usually referring to contact between the occlusal surfaces.

Occlusion of complete denture:

The static relationship between the incising and masticatory surfaces of the maxillary and mandibular teeth analogues. (GPT-8)

Centric occlusion:

The occlusion of opposing teeth when the mandible is in centric relation. This may or may not coincide with maximum intercuspation. (It is tooth-to-tooth relation).

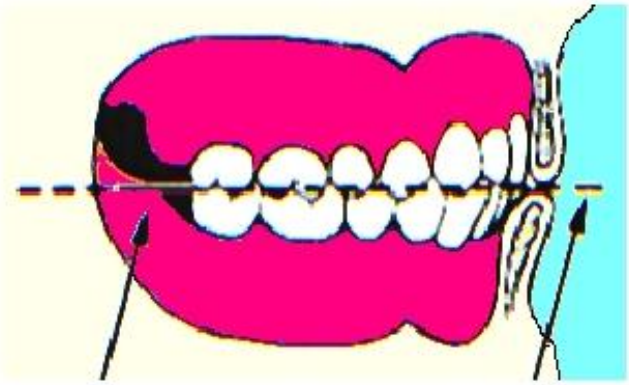

The Retromolar Pad's Relationship to the Natural Dentition.

Centric relation:

It is the most retruded relation of mandible to the maxillae when the condyles are in most posterior unstrained position in the glenoid fossae from which lateral movement can be made, at given degree of jaw separation. (It is bone-to-bone relation)

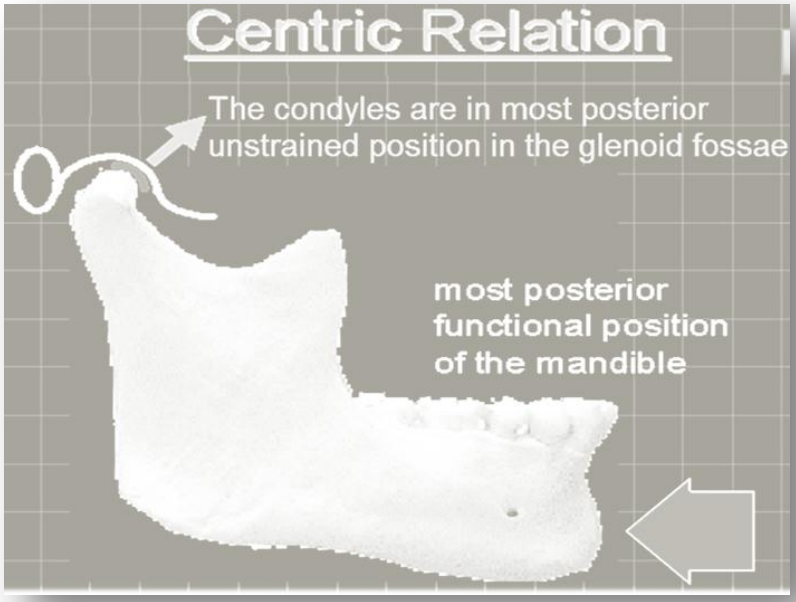

Maximum intercuspation (intercuspal position):

The complete intercuspation of the opposing teeth, independent of condylar position.

If in maximum intercuspation the condyles are physiologically centered, then both the maximum intercuspal position and the centric occlusion position are the same. However, if maximum intercuspation occurs with the condyles being out of centricity, then both positions would not coincide, with the maximum intercuspation in that case,

referred to as the habitual closure, and considered as an eccentric position.

In complete denture construction it is essential that centric occlusion is in harmony with centric relation even though this condition doesn't always occur in natural dentition, so the dentist is responsible to record centric relation, and maintain this relationship in the laboratory procedure during mounting and arrangement of teeth in centric occlusion.

In centric occlusion, the buccal cusps of the mandibular teeth contacts the central fossa of maxillary teeth, while the lingual cusps of the maxillary teeth fill into the central fossa of the mandibular teeth. This facial overlap prevents cheek biting when the denture are completed.

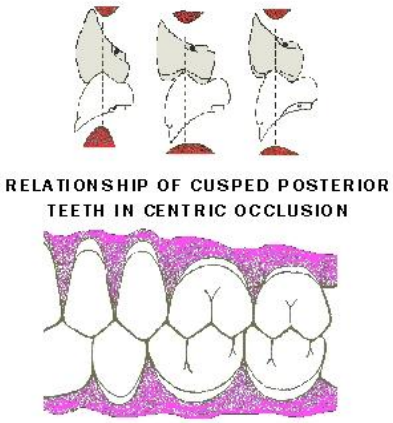

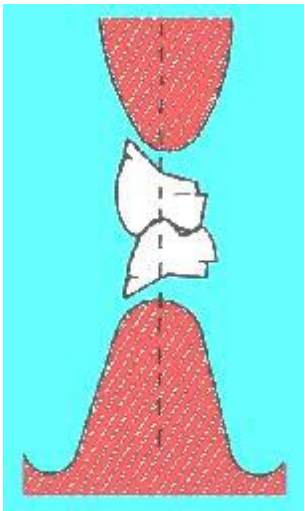

Importance of centric relation:

It is a significant jaw position especially in denture construction due to that it is:

- Reproducible.
- Recordable.
- Stable

- Regarded as a reference point for setting the teeth in maximal intercuspal position.

Eccentric occlusion:

Any occlusion other than centric occlusion (protrusive, right and left lateral movement).

Concepts of complete denture occlusion:

1. Balanced occlusion.
2. Monoplane or non-balanced occlusion.
3. Lingualized occlusion.

Balanced occlusion:

Means the simultaneous contacting of the upper and lower teeth on the right and left and in the anterior and posterior occlusal areas (working, balancing and protrusive).

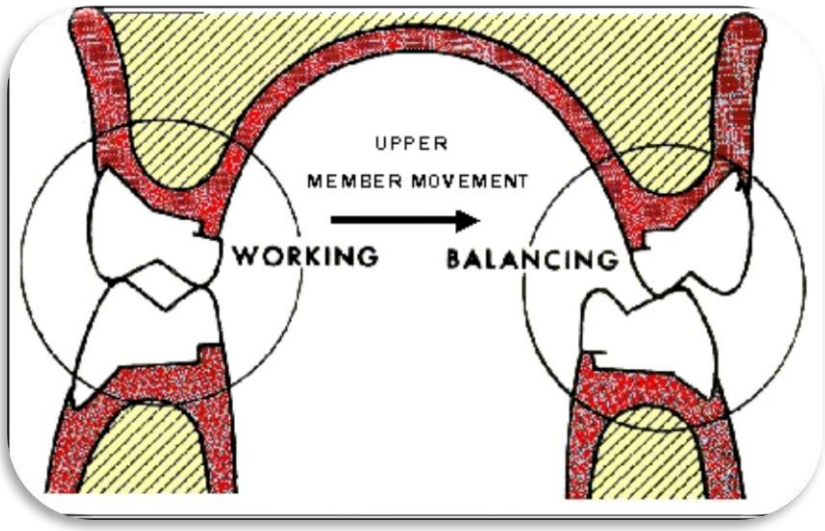

Working side:

The side toward which the mandible move in a lateral excursion.

Balancing side (non-working side):

That side of the mandible that moves toward the median line in a lateral excursion (the side opposite the working side).

CENTRIC POSITION	PROTRUSIVE POSITION	LATERAL POSITION	
		Working	Nonworking
Anterior and posterior teeth contact	All maxillary and mandibular teeth contact	Posterior teeth make contact	Posterior teeth make contact.

BALANCED OCLUSION

In lateral position, working side

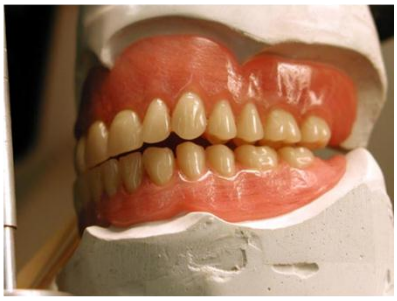

In lateral position, balancing side

Working or functional occlusion:

Occurs when the facial or buccal cusps of maxillary teeth meet the facial cusps of the mandibular teeth and the lingual cusps of the maxillary teeth meet the lingual cusps of the mandibular teeth.

The relationship is not cusp tip to cusp tip, but cusp tip into cusp "valley" with each maxillary cusp distal to the corresponding mandibular cusp. Working occlusion enable a person to hold and crush food.

Bilateral Balanced Denture Occlusion with Anatomic Posterior Denture Teeth

Balancing occlusion:

Occurs simultaneously on the opposite side from working occlusion. Balancing occlusion functions is to maintain the dentures in position during lateral excursive movements.

In balancing occlusion, the lingual cusps of maxillary teeth contact the buccal cusps of the mandibular teeth. In many techniques, balancing contacts are necessary only on the second molar.

Protrusive occlusion:

It is the relation acquired by the mandible when it moves in protrusive direction from centric position.

The protrusive direction are downward and forward.

When the condyles travels in this direction, it brings the anterior teeth into a position favorable for incision .

In protrusive balance, the distal inclines of the maxillary buccal cusps contact the mesial inclines of the mandibular buccal cusps.

Protrusive balancing contact may occurs on lingual cusps this help to maintain denture stability.

Importance of balanced occlusion:

1. It avoid displacement of denture and help in its stability during functional and non-functional movements .
2. It help in earlier repositioning of denture, which become displaced during mastication.
3. It minimize period required for adaptation of patient to the denture due to its stability .

4. Prevent trauma to the supporting tissue since the pressure is equally distributed on the teeth.

Factors controlling the balanced occlusion:

1. Inclination of condylar guidance.
2. Inclination of Incisal guidance.
3. Cusp height.
4. Orientation of the occlusal plane.
5. Prominence of the compensating curve.

Monoplane occlusion:

Monoplane occlusion characterized by occlusal contacts of maxillary and mandibular teeth initially in maximum intercuspation.

The disocclusion of posterior teeth occurs because of their arrangement in a single plane, and the contact of the anterior teeth during movement of the mandible (teeth are set in a flat plane with no vertical overlap of the anterior teeth).

Indications of the monoplane occlusion (neutrocentric concept):

1. Flat ridge(s)
2. Class II jaw relations
3. Class III jaw relations
4. Handicapped patients
5. Cross bite
6. Doubtful or Without any perfect centric relation records

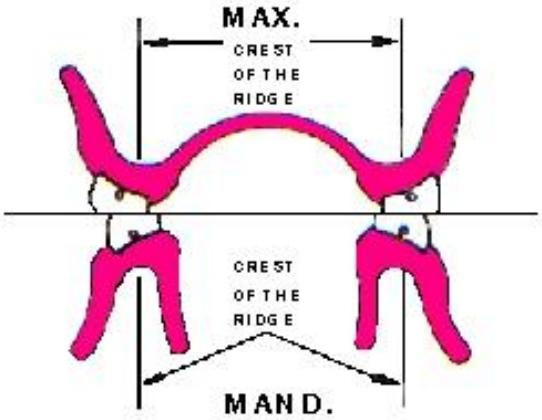

POSTERIOR HORIZONTAL OVERLAP
OF FLAT PLANE TEETH.

Lingualized occlusion:

The maxillary lingual cusps are the main functional occlusal elements. These may oppose mandibular 0º or shallow cusp teeth in balanced or non-balanced patterns depending on the needs of the patient.

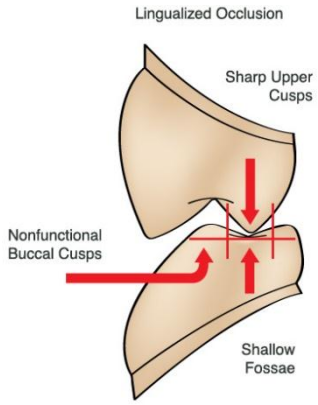

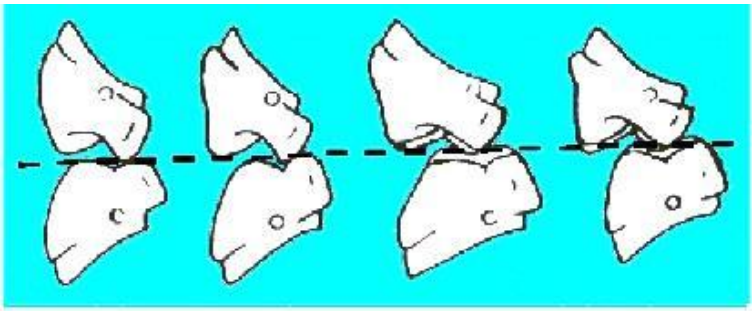

Occlusal relationships of posterior teeth
in Lingualized Occlusion.

Advantages:

1. The presence of a cusped tooth in the maxillary premolar and first molar regions looks more natural when compared to a zero° tooth.
2. The use of maxillary lingual cusps could be expected to centralize the occlusal forces and reduce the frictional resistance of flat teeth sliding over one another.

3. Additional stability can be gained during para-functional movements.

Try-in appointment:

In the try-in appointment (clinical-stage) the teeth are tried in before processing them in acrylic resin to:

1. Verify the maxillo-mandibulare records that were made without teeth (tentative record).
2. Test for the acceptance of the established vertical dimension of occlusion.
3. Determine if the positions of the teeth and the contours of the denture base are compatible with the surrounding oral environment.
4. Evaluate the arrangement for esthetic requirements.
5. Make additional inter-occlusal maxillo-mandibular records if needed for further adjustment of articulator for excursive movements after the try-in like protrusive.